

Limb alignment in computer-assisted minimally-invasive unicompartmental knee replacement

G. Keene,
D. Simpson,
Y. Kalairajah

From Sportsmed-SA
Orthopaedic Clinic,
Adelaide, South
Australia

Twenty patients underwent simultaneous bilateral medial unicompartmental knee arthroplasty. Pre-operative hip-knee-ankle alignment and valgus stress radiographs were used to plan the desired post-operative alignment of the limb in accordance with established principles for unicompartmental arthroplasty. In each patient the planned alignment was the same for both knees. Overall, the mean planned post-operative alignment was to 2.3° of varus (0° to 5°).

The side and starting order of surgery were randomised, using conventional instrumentation for one knee and computer-assisted surgery for the opposite side.

The mean variation between the pre-operative plan and the achieved correction in the navigated and the non-navigated limb was 0.9° (SD 1.1; 0° to 4°) and 2.8° (SD 1.4; 1° to 7°), respectively. Using the Wilcoxon signed rank test, we found the difference in variation statistically significant ($p < 0.001$).

Assessment of lower limb alignment in the non-navigated group revealed that 12 (60%) were within $\pm 2^\circ$ of the pre-operative plan, compared to 17 (87%) of the navigated cases.

Computer-assisted surgery significantly improves the post-operative alignment of medial unicompartmental knee arthroplasty compared to conventional techniques in patients undergoing bilateral simultaneous arthroplasty. Improved alignment after arthroplasty is associated with better function and increased longevity.

Total knee arthroplasty (TKA) and medial unicompartmental knee arthroplasty (UKA) have been shown to give good long-term results,¹⁻⁶ although lateral UKA does not seem to fare as well.^{7,8}

One of the aims of partial or total knee replacement surgery is to insert the prosthesis accurately so as to restore the alignment of the lower limb in the coronal, sagittal and rotational planes, in order to relieve symptoms and improve function. Of these alignments, the coronal is the most important. Survival of the implant depends on patient selection, age, weight, gender and level of activity.^{9,10} Other factors, such as sepsis, bony and prosthetic fractures, or polyethylene failure will affect the survival of the implant, but the most important variable determined by the surgeon is prosthetic alignment.¹¹

A TKA is anatomically-aligned only when the mechanical axis passes through the mid-points of the hip, knee and angle in a straight line, and the joint line is horizontal to the ground in the coronal plane. Both medial and lateral compartments will then be equally loaded, distributing equal stresses throughout

the prosthesis.¹² This is a mechanical axis of 0°.

In a normal knee, however, the mechanical load is predominantly medial, a reflection of the greater surface area for weight-bearing compared to the lateral side.¹³

UKA was first introduced in the 1970s to treat arthritis of a single compartment, with satisfactory early results.^{3-6,14,15} The reported advantages over TKA are that there is less trauma to bone and soft-tissue, less blood loss and a more rapid post-operative recovery. The advent of minimally-invasive surgery has further reduced the operative trauma and led to even faster recovery. However, there is a suggestion that, even with contemporary instrumentation, minimally-invasive UKA is not as accurate as open UKA in anteroposterior tibial placement or in the post-operative alignment of the limb.¹⁶

The correct post-operative limb alignment of a medial UKA is still not certain. Some authors¹⁷ state that the object of surgery is to simply replace the worn intra-articular joint surface and restore the mechanical axis of the lower limb to its physiological position before

■ G. Keene, MB BS,
FRACS(Orth), FASMF,
Consultant Orthopaedic
Surgeon
■ D. Simpson, FRCS(Tr &
Orth), Orthopaedic Research
Fellow
■ Y. Kalairajah, MA, MPhil,
FRCS(Tr & Orth),
Orthopaedic Research
Fellow
Sportsmed-SA Orthopaedic
Clinic, 32 Payneham Road,
Stepney 5069, Adelaide,
South Australia.

Correspondence should be
sent to Dr G. Keene; e-mail:
gregkeene@ozemail.com.au

©2006 British Editorial
Society of Bone and
Joint Surgery
doi:10.1302/0301-620X.88B1.
16266 \$2.00

J Bone Joint Surg [Br]
2006;88-B:44-8.
Received 12 January 2005;
Accepted after revision
16 August 2005

the onset of degenerative changes. This differs significantly from the rationale of 0° mechanical axis alignment for performing a TKA, and after operation will usually leave a medial arthritic knee in slight varus and a lateral arthritic knee in slight valgus. In UKA, a patient-specific physiological alignment is often achieved by undercorrecting the angular deformity while protecting the healthy opposite compartment, but excessive undercorrection, such as with a thin tibial insert, should be avoided,¹⁸ as this can lead to poor results and early failure. Studies of lower limb alignment in the normal population have shown the tibiofemoral axis to be slightly varus¹⁹ and this supports the philosophy of slightly undercorrecting the deformity in varus knees. Some authors advocate restoring the mechanical axis to pass through the centre of the knee joint.²⁰ However, overcorrection of the varus deformity is thought to accelerate degenerative change in the lateral compartment,⁶ although this has also been debatable.²¹

Our own pre-operative surgical aim when undertaking UKA is to recreate the patient's own physiological mechanical axis with a balanced knee as it had been before the onset of osteoarthritis. In most patients with a varus deformity this results in a slightly varus knee, which is often referred to as 'slightly undercorrected', but we would prefer to refer to it as corrected to the normal varus alignment. This principle is the same for the less frequent valgus deformity of the knee. We also agree with the principle of never performing ligamentous or soft-tissue releases in UKA knees in order to achieve a naturally balanced and aligned knee, in contrast to TKA, where ligamentous and soft-tissue releases are often performed to align and balance the knee at 0° .

With the recent introduction of computer-assisted surgery we now have the ability to restore more accurately an individual patient's true mechanical axis. Our hypothesis was that medial UKA undertaken using computer-assisted surgery would significantly improve post-operative limb alignment compared to standard instrumented techniques.

Patients and Methods

Between July 2003 and June 2004, we recruited 20 patients into our prospective randomised matched-pair trial. All had medial compartment osteoarthritis and were awaiting bilateral simultaneous UKA. Signed consent for involvement in the study was received from all patients. There were 15 men and five women, with a mean age of 60 years (51 to 78). Bilateral simultaneous medial UKA was performed on all patients.

Pre-operative hip-knee-ankle alignment and valgus stress radiographs were used to plan the desired post-operative limb alignment in accordance with established principles for unicompartmental arthroplasty to slightly undercorrect the deformity by 2° . For example, if the radiograph for alignment measured 5° of varus and the valgus stress radiograph achieved 4° of correction, then the pre-operative plan was set at the corrected alignment -2°

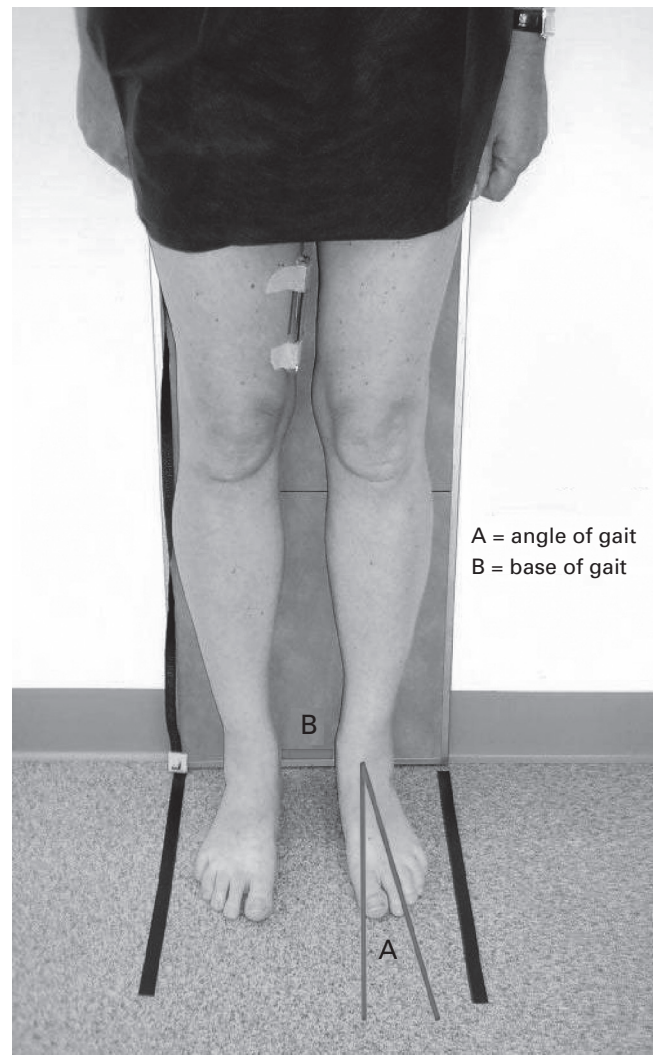


Fig. 1

Position of patient for hip-knee-ankle radiographs. A, deviation from the sagittal plane of the line of progression of the foot; B, distance between malleoli.

($5 - 4 + 2 = 3^\circ$ of varus). In each individual patient the planned alignment was the same for both knees. Overall, the average pre-operative planned alignment was 2.3° of varus (0° to 5°).

Knees were randomised to either computer-assisted surgery or the conventional surgical approach, and the starting order was determined by sealed envelope opened on the day of surgery. Computer-assisted surgery was used on 13 right knees and seven left knees. The Preservation UKA (DePuy, Leeds, UK) was used in all cases. Seven patients had fixed-bearing all-polyethylene tibial implants, eight had fixed-bearing metal-backed tibial implants, and five had mobile-bearing tibial implants. The surgical technique for all three bearing types is identical up to the point of insertion of the implant, and, based on our previous experience was not thought to affect the objective of the study.

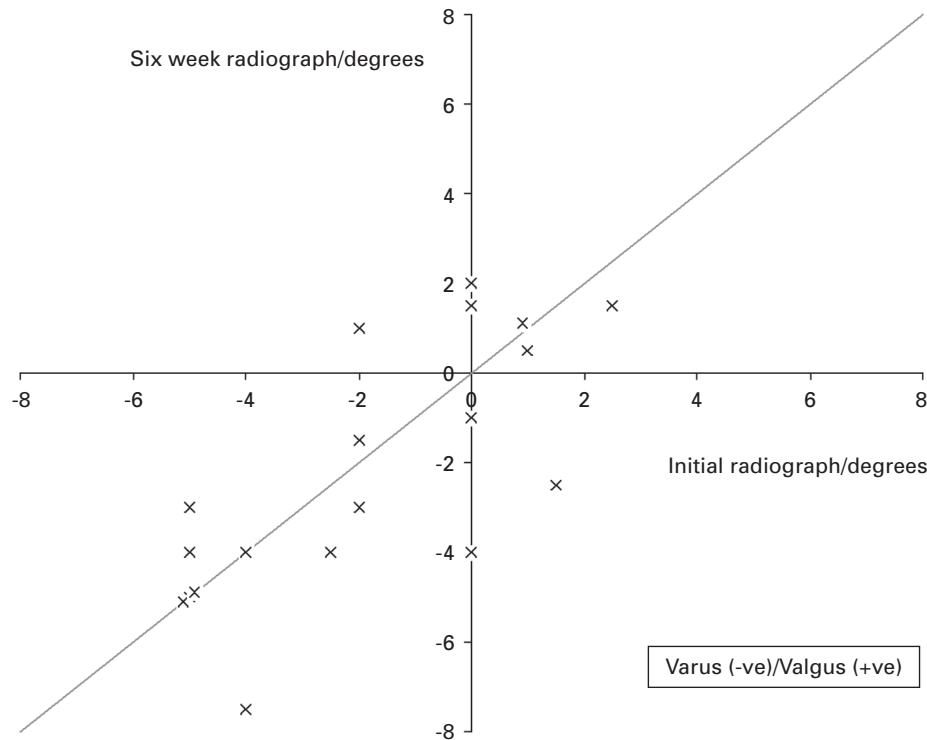


Fig. 2

Scatter plot of variation in lower limb alignment as hip-knee-ankle radiographs taken six weeks apart (non-operated limb in patients undergoing unicompartmental knee arthroplasty). Varus (negative)/valgus (positive).

In this series of patients we found that the pre-operative planned alignment was achieved with good ligamentous balance at surgery. However, we have had other cases where the planned alignment could not be achieved at surgery owing to excessive ligamentous tightness or laxity. It was then altered to allow a balanced knee. We think it is a strength of computer-assisted surgery that this fine-tuning of the relationship between soft-tissue balance and alignment is possible.

All patients were subjected to a protocol that involved a pre-operative hip-knee-ankle standard standing alignment radiograph and a valgus stress film of both knees to document the varus deformity and the intended angle of correction with regard to soft-tissue correction and balancing. A further hip-knee-ankle standard standing alignment radiograph was taken six weeks after surgery to record the actual correction achieved.

For the hip-ankle-knee radiographs, we positioned the patients in their normal stance with respect to angle and base of gait in full extension, which we felt more accurately simulated the weight-bearing forces through the knee during walking. The angle of gait is the line of progression of the foot in relation to the sagittal plane during normal walking. The base of gait is the approximate distance between the malleoli during normal walking (Fig. 1). These

measurements were recorded and used again in the radiograph taken six weeks after operation. A standardised 100-mm radiographic marker was placed on the medial aspect of the thigh in all patients for scaling the films.

The technique for our alignment films was previously validated by undertaking hip-knee-ankle radiographs before and six weeks after operation on 19 patients who were undergoing unilateral UKA. The varus/valgus alignment of the non-operated leg was measured from both sets of films and a good repeatability was achieved, with an average difference of 0.2° (Fig. 2). We do not feel that computed tomographic (CT) techniques for limb alignment in UKA are sensitive enough, as they are not weight-bearing. We developed our weight-bearing radiograph technique to overcome this difficulty.

All surgery was performed by the senior author (GK), who has previously performed more than 1000 instrumented UKA cases (250 Preservation) and 30 computer-assisted surgery UKA cases (Preservation) using the Ci system jointly developed by DePuy and BrainLab (Munich, Germany). The software used was the Ci Preservation Knee version 1.0. Owing to the demands of computer-assisted surgery, operation on each knee was carried out sequentially under individual tourniquet control and the duration of inflation of the tourniquet noted separately.

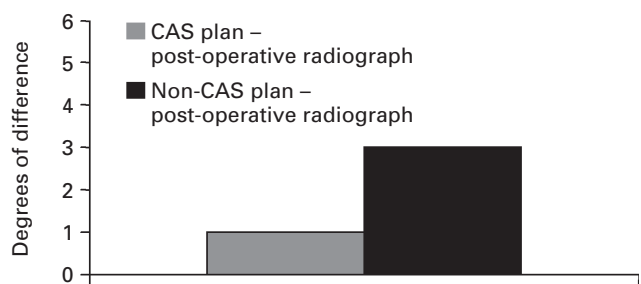


Fig. 3

The difference between the pre-operatively planned and post-operatively achieved alignment.

The difference between the pre-operative planned correction and the actual correction achieved in lower limb alignment films taken at six weeks was recorded in all patients. Statistical analysis was carried out using non-parametric methods (SAS Statistical Software; SAS Institute Inc., Cary, North Carolina). Ethical approval had been granted.

Results

In each individual patient, the planned correction in both knees was the same. Consequently, in both the navigated and the non-navigated knees the mean planned pre-operative correction was to 2.3° of varus (SD 1.8; 0° to 5°).

In the navigated knees, the actual mean correction achieved was to 1.3° of varus (SD 2.1; 5.5° varus to 2° valgus), including varus and valgus alignments. The mean variation between the pre-operative planned alignment and the actual achieved alignment was 0.9° (SD 1.1; 0° to 4°).

In the non-navigated knees, the actual mean achieved correction was to 0.5° of varus (SD 2.9; 6° varus to 5° valgus), including varus and valgus alignments. The mean variation between the pre-operative planned alignment and the actual achieved alignment was 2.8° (SD 1.4; 1° to 7°). These differences and ranges are summarised to the nearest degree in Figure 3.

Using the Wilcoxon signed rank test, this difference in planned *versus* achieved alignment of 1.9° between the groups was found to be statistically highly significant ($p < 0.001$).

Assessment of alignment of the lower limb in the non-navigated group revealed that only 12 (60%) were within $\pm 2^\circ$ of the pre-operative plan, compared to 17 (87%) of the navigated cases; five (27%) patients therefore had their limb alignment improved by the use of computer-assisted surgery.

The mean tourniquet time for navigated surgery was 70 minutes, compared with 53 minutes for non-navigated surgery.

No complications were reported in either group.

Discussion

The long-term outcome of a TKA or UKA depends on accurate post-operative limb alignment. In TKA, prosthetic

loosening is more readily seen with a medially-displaced mechanical axis, and a recommendation to align the knee in neutral, loading both compartments evenly or in slight valgus, is advised.^{22,23}

In medial UKA, the ideal post-operative limb alignment is not clear, with some surgeons feeling that UKA is primarily a ligament balancing procedure. The benefit of computer-assisted surgery is the ability to locate bony landmarks in the lower limb from which accurate alignment can be determined so that the preferred alignment and ligamentous balance of the surgeon can be achieved. Ligamentous balance is assessed in the normal manner, but with the added advantage that the alignment can be accurately viewed and recorded at different tensions.

We did not attempt to evaluate alignment of the component because of the difficulty of relating the software images and angles of the intra-operative positions of the components selected to the post-operative radiographs. We acknowledge that the position of the prosthesis is important with regard to wear and survival. This will be the subject of a future study.

The literature on computer-assisted surgery is limited. Comparative studies evaluating post-operative alignment in conventional and navigated implanted TKA show very encouraging results. A statistically significant improvement in positioning the implant in navigated knees has been achieved,^{24,25} and despite the learning curve, superior results are attainable.²⁶ Statistically significant improvements have been shown²⁷ in the positioning of the implant in cadavers using computer-assisted surgery compared to current techniques, and early results are promising.²⁸


We are only aware of two papers^{29,30} comparing navigated *versus* conventionally implanted UKA. The first of these two studies matched 30 navigated medial UKA with 30 conventionally implanted prostheses. Post-operatively, radiological assessments of the prosthesis were made according to five radiological parameters. In the navigated group, 18 of the implants satisfied all criteria, whereas only six did so in the non-navigated group; this difference was significant ($p < 0.01$).²⁹ The second study prospectively reviewed two groups of 20 patients undergoing medial UKA, either conventionally or with navigation. In the navigated group there was a statistically significant post-operative improvement in the coronal mechanical femorotibial axis ($p = 0.008$).³⁰ In neither of these studies was the procedure minimally invasive.

In our prospective randomised controlled trial we have shown a statistically significant improvement in post-operative alignment of the lower limb following minimally invasive UKA using computer-assisted surgery rather than conventional techniques. In our trial, computer-assisted surgery facilitated a 27% increase in patients in whom post-operative lower limb alignment was within $\pm 2^\circ$ of their pre-operative plan. The mean tourniquet time was higher in the computer-assisted group, but there was a trend towards reducing this as the study progressed and we

became more comfortable with the equipment. This study was undertaken after we had done approximately 20 computer-assisted minimally-invasive UKAs. We feel that the learning curve with such a new device is in the region of 20 cases, but will of course vary.

Our experience from this study suggests that computer-assisted surgery will allow improved lower limb alignment following implantation of a medial UKA. Based on established studies linking poor alignment with early failure, this should allow improved long-term survival of the implant in these patients.

Supplementary Material

 A further opinion by Mr Christopher Ackroyd is available with the electronic version of this article on our website at www.jbjs.org.uk

Although none of the authors has received or will receive benefits for personal or professional use from a commercial party related directly or indirectly to the subject of this article, benefits have been or will be received but will be directed solely to a research fund, foundation, educational institution, or other nonprofit organisation with which one or more of the authors are associated.

References

1. **Buechel FF Jr.** Long-term follow-up after mobile-bearing total knee replacement. *Clin Orthop* 2002;404:40-50.
2. **Fetzer GB, Callaghan JJ, Templeton JE, et al.** Posterior cruciate-retaining modular total knee arthroplasty: a 9 to 12 year follow-up investigation. *J Arthroplasty* 2002;17:961-6.
3. **Deshmukh RV, Scott RD.** Unicompartmental knee arthroplasty: long-term results. *Clin Orthop* 2001;392:272-8.
4. **Svard UCG, Price AJ.** Oxford medial unicompartmental knee arthroplasty: a survival analysis of an independent series. *J Bone Joint Surg [Br]* 2001;83-B:191-4.
5. **Heck DA, Marmor L, Gibson A.** Unicompartmental knee arthroplasty: a multi-centre investigation with long term follow-up evaluation. *Clin Orthop* 1993;286:154-9.
6. **Murray DW, Goodfellow JW, O'Connor JJ.** The Oxford medial unicompartmental arthroplasty. *J Bone Joint Surg [Br]* 1998;80-B:983-9.
7. **Ashraf T, Newman JH, Evans RL, Ackroyd CE.** Lateral unicompartmental knee replacement survivorship and clinical experience over 21 years. *J Bone Joint Surg [Br]* 2002;84-B:1126-30.
8. **Robinson BJ, Rees JL, Price AJ, et al.** Dislocation of the bearing of the Oxford lateral unicompartmental arthroplasty: a radiological assessment. *J Bone Joint Surg [Br]* 2002;84-B:653-7.
9. **Foran JR, Mont MA, Etienne G, Jones LC, Hungerford DS.** The outcome of total knee arthroplasty in obese patients. *J Bone Joint Surg [Am]* 2004;86-A:1609-15.
10. **Harryson OL, Robertsson O, Nayfeh JF.** Higher cumulative revision rate of knee arthroplasties in younger patients with osteoarthritis. *Clin Orthop* 2004;421:162-8.
11. **Moreland JR.** Mechanisms of failure in total knee arthroplasty. *Clin Orthop* 1988; 226:49-64.
12. **Hsu HP, Garg A, Walker PS, Spector M, Ewald FC.** Effect of knee component alignment on tibial load distribution with clinical correlation. *Clin Orthop* 1989;248: 135-44.
13. **Kettelkamp DB, Jacobs AW.** Tibiofemoral contact area: determination and implications. *J Bone Joint Surg [Am]* 1972;54-A:349-56.
14. **Marmor L.** Unicompartmental knee arthroplasty: ten to 13 year follow-up study. *Clin Orthop* 1988;226:14-20.
15. **Scott RD, Cobb AG, McQueary FG, Thornhill TS.** Unicompartmental knee arthroplasty: eight to 12 year follow-up evaluation with survivorship analysis. *Clin Orthop* 1991;271:96-100.
16. **Fisher DA, Watts M, Davis KE.** Implant position in knee surgery: a comparison of minimally invasive, open unicompartmental and total knee arthroplasty. *J Arthroplasty* 2003;18(Suppl 7):2-8.
17. **Cartier Ph, Deschamps G.** Surgical principles of unicompartmental knee. Replacement. In: Cartier Ph, Epinette JA, Deschamps G, Hernigou Ph, eds. *Unicompartmental knee arthroplasty*. Paris: Expansion Scientifique Francaise, 1977.
18. **Ridgeway SR, McAuley JP, Ammeen DJ, Engh GA.** The effect of alignment of the knee on the outcome of unicompartmental knee replacement. *J Bone Joint Surg [Br]* 2002;84-B:351-5.
19. **Hsu RWW, Himeno S, Coventry MB, Chao YS.** Normal axial alignment of the lower extremity and load-bearing distribution at the knee. *Clin Orthop* 1990;255: 215-27.
20. **Emerson RH Jr, Hansborough T, Reitman RD, Rosenfeldt W, Higgins LL.** Comparison of a mobile with a fixed bearing unicompartmental knee implant. *Clin Orthop* 2002;404:62-70.
21. **Emerson RH Jr, Head WC, Peters PC Jr.** Soft-tissue balance and alignment in medial unicompartmental knee arthroplasty. *J Bone Joint Surg [Br]* 1992;74-B:807-10.
22. **Insall JN, Binazzi R, Soudry M, Mestriner LA.** Total knee arthroplasty. *Clin Orthop* 1985;192:13-22.
23. **Ritter MA, Faris PM, Keating EM, Meding JB.** Postoperative alignment of total knee replacement: its effect on survival. *Clin Orthop* 1994;299:153-6.
24. **Chauhan SK, Scott RG, Braidahl W, Beaver RJ.** Computer-assisted knee arthroplasty versus a conventional jig-based technique. *J Bone Joint Surg [Br]* 2004;86-B: 372-7.
25. **Jenny J-Y, Boeri C.** Navigated implantation of total knee prosthesis: a comparative study with conventional techniques. *Z Orthop Ihre Grenzgeb* 2001;139:117-19 (in German).
26. **Mielke RK, Clemens U, Jens J-H, Kershally S.** Navigation in knee endoprosthesis implantation: preliminary experiences and prospective comparative study with conventional implantation technique. *Z Orthop Ihre Grenzgeb* 2001;139:109-16 (in German).
27. **Chauhan SK, Clark GW, Lloyd S, et al.** Computer-assisted total knee replacement: a controlled cadaver study using a multi-parameter quantitative CT assessment of alignment (the Perth CT Protocol). *J Bone Joint Surg [Br]* 2004;86-B:818-23.
28. **Stulberg SD, Loan P, Sarin V.** Computer-assisted navigation in total knee replacement: results of an initial experience in thirty-five patients. *J Bone Joint Surg [Am]* 2002;84-A(Suppl 2):90-8.
29. **Jenny JY, Boeri C.** Unicompartmental knee prosthesis implantation with a non-image-based navigation system: rationale, technique, case-control comparative study with a conventional instrumented implantation. *Knee Surg Sports Traumatol Arthrosc* 2003;11:40-5.
30. **Perlick L, Bathis H, Tingart M, et al.** Minimally invasive unicompartmental knee replacement with a nonimage-based navigation system. *Int Orthop* 2004;28:193-71.