

Surgical Treatment of Lateral Posterolateral Instability of the Knee Using Biceps Tendon Procedures

Gregory C. Fanelli, MD

Abstract: Posterolateral instability (PLI) is common with posterior cruciate ligament tears and is less common with anterior cruciate ligament tears, and isolated PLI is rare. There are varying degrees of PLI with respect to pathologic external tibial rotation, and varus laxity. Surgical treatment of PLI must address all components of the PLI (popliteus tendon, popliteofibular ligament, lateral collateral ligament, and the lateral-posterolateral capsule), and other structural injuries. Successful posterior cruciate ligament and anterior cruciate ligament surgery depends upon recognition and treatment of posterolateral corner injuries.

Key Words: posterolateral instability, biceps femoris tendon transfer, posterolateral capsular shift

(*Sports Med Arthrosc Rev* 2006;14:37-43)

Posterolateral instability (PLI) is common with posterior cruciate ligament (PCL) tears and is less common with anterior cruciate ligament (ACL) tears, and isolated PLI is rare. There are varying degrees of PLI with respect to pathologic external tibial rotation, and varus laxity. Surgical treatment of PLI must address all components of the PLI [popliteus tendon (PT), popliteofibular ligament (PFL), lateral collateral ligament (LCL), and the lateral-posterolateral capsule], and other structural injuries. Successful PCL and ACL surgery depends on recognition and treatment of posterolateral corner injuries.

This article is one of the eight dedicated to PLI of the knee. Other articles discuss anatomy and biomechanics, physical examination, diagnostic imaging, nonsurgical treatment, and free graft and capsular procedures for surgical reconstruction of PLI. The purpose of this article was to discuss the technique of biceps tendon transfer surgical reconstruction for PLI of the knee.²

INCIDENCE

Acute PLI occurs most frequently in our practice in association with PCL tears and combined ACL and PCL tears (ACL-PCL), and rarely in conjunction with ACL

tears, or as an isolated acute posterolateral corner injury.^{3,4}

SURGICAL ANATOMY

The important surgical anatomy of the posterolateral corner of the knee includes the LCL, the PT, the PFL, and the lateral and posterolateral capsule. The purpose of any surgical reconstruction is to perform a primary repair and/or reconstruct each of these injured structures to recreate the function of these structures. The structures of the lateral and posterolateral corner function to resist varus stress, resist posterior tibial translation near full extension, and resist external tibial rotation. Damage to the posterolateral and lateral structures of the knee results in variable pathologic laxity in posterior tibial translation, varus rotation, and external tibial rotation, depending upon the degree of injury to the knee.^{16,18,19}

EVALUATION OF PLI OF THE KNEE

In our experience, the most common mechanism of injury for an isolated LCL injury is a direct blow to the medial side of the knee with the foot planted. This leads to increased varus rotation that is maximum at 30° of knee flexion. Isolated LCL injury is very uncommon in our practice, and the examiner should be aware of a more complex injury pattern. A direct blow to the anterior medial proximal tibia with the foot planted is the most common mechanism of injury to the posterolateral corner of the knee that we see in our practice. This usually also involves injury to the PCL and ACL as well.^{3,4}

Patients presenting with acute PLI may have posterolateral knee pain, peroneal nerve symptoms (sensory and/or motor disturbances), and most likely associated ligament pathology such as PCL and/or ACL tears. Patients with chronic PLI may present with hyperextension instability, posterolateral pain, peroneal nerve symptoms, varus thrust, functional instability, and medial or lateral joint line pain.³⁻⁵

CLASSIFICATION OF PLI OF THE KNEE

We have described 3 types of PLI: A, B, and C.⁸ PLI includes at least 10° of increased tibial external rotation compared with the normal knee at 30° of knee flexion (positive dial test and external rotation thigh foot angle test), and variable degrees of varus instability depending on the injured anatomic structures.⁸ PLI type A has

From the Orthopaedic Surgery, 100 North Academy Avenue, Danville, PA 17821.

Reprints: Gregory C. Fanelli, MD, Orthopaedic Surgery, 100 North Academy Avenue, Danville, PA 17821 (e-mail: gfanelli@geisinger.edu). Copyright © 2006 by Lippincott Williams & Wilkins

increased external rotation only, corresponding to injury to the PFL, and PT only. PLI type B presents with increased external rotation, and mild varus of approximately 5 to 10 mm increased lateral joint line opening with a firm end point to varus stress at 30° knee flexion. This occurs with damage to the PFL, PT, and attenuation of the fibular collateral ligament. PLI type C presents with increased tibial external rotation, and varus instability, 10 mm greater than the normal knee, without a firm end point tested at both 0° and 30° of knee flexion with varus stress. This occurs with injury to the PFL, PT, fibular collateral ligament, and lateral capsular avulsion in addition to cruciate ligament disruption. Subsequently, the physical examination will vary depending on the type of PLI. All types of PLI will demonstrate increased external rotation as compared with the patient's uninjured knee; however, the degree of varus laxity will vary depending on the magnitude of injury to the involved structures. Multiple physical examination tests should be utilized (see article in this section on physical examination of the posterolateral corner of the knee) to determine the classification of pathologic motion because this will determine what will need to be addressed surgically.^{3-5,8}

INDICATIONS FOR SURGICAL TREATMENT

Isolated low-grade posterolateral complex injuries may do well with nonoperative treatment; however, in our experience, the low-grade isolated posterolateral corner injury is uncommon. Posterolateral corner injuries are most commonly combined with PCL injuries, and are part of a multiple ligament-injured knee complex.⁹ These combined instability knees are best treated with surgical correction of all components of the instability. Chronic posterolateral injuries often present with functional instability, and surgical reconstruction is the treatment of choice. Cases with bony varus may be best served with high tibial valgus osteotomy before knee ligament reconstruction (Fig. 1).

The goal of the surgery is to eliminate the pathologic motion by correcting the abnormal external tibial rotation and by correcting the varus instability. Because most cases are combined instabilities, all components of the instability must be corrected.

SURGICAL TREATMENT STRATEGY

Surgical treatment for repair-reconstruction of posterolateral knee injury include primary repair with fixation devices, capsular advancement or capsular shift procedures, biceps tendon transfer procedures, and free graft procedures (autograft or allograft).

Our surgical treatment strategy for correction of acute PLI is to correct the abnormal motion in the planes of external rotation and varus rotation, perform a primary repair of the injured structures when possible, reduce pathologic posterolateral capsule volume, and create a lateral and posterolateral structural soft tissue support to augment the primary repair process. This strut of strong autograft or allograft tissue recreates the

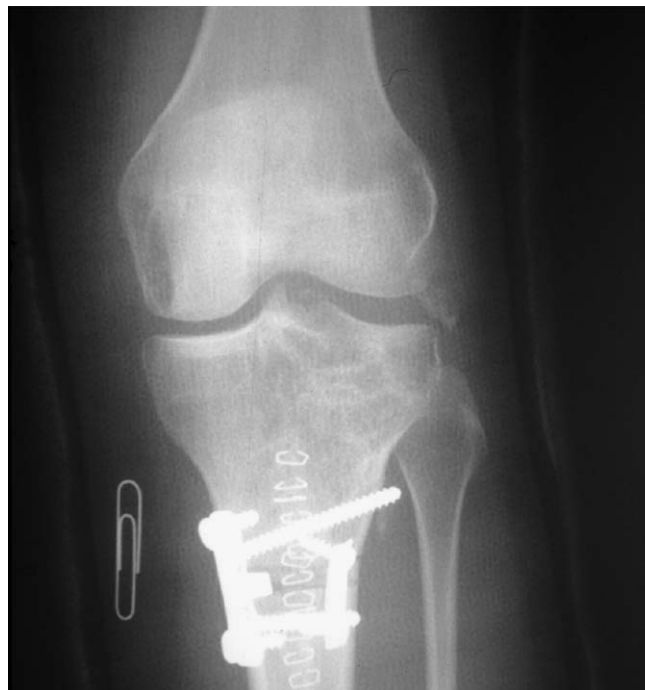

FIGURE 1. Opening wedge high tibial osteotomy performed before posterolateral reconstruction to correct varus malalignment (with permission, Gregory C. Fanelli, MD).

function of the LCL and the PFL, and helps to reinforce the posterolateral capsule. This strut of allograft or autograft tissue may course from the lateral femoral epicondylar region to the head of the fibula, or to the head of the fibula and the posterolateral aspect of the tibia. It is also important to address injuries to the cruciate ligaments, menisci, medial knee ligaments, articular cartilage, and fractures as indicated.¹¹

BIOMECHANICS OF SURGICAL RECONSTRUCTION

The surgical reconstruction for PLI involves the creation of ligamentous substitutes positioned to resist varus rotation and posterolateral tibial rotation. All these procedures involve the creation of structural bands from either the fibular head or the posterolateral corner of the tibia to the region of the lateral femoral epicondyle. Structural bands are created from existing structures, autografts, or allografts. It is important in planning a surgical reconstruction to understand the ligament length relationships of the lateral knee so that tissues can be placed in near isometric positions and in positions of optimal mechanical advantage to resist varus rotation and posterolateral tibial rotation.¹¹

The isometry of the lateral side of the knee has been studied at the University of Washington.¹⁷ The study investigated length relationships between the fibular head and the lateral aspect of the femur. The study demonstrates that the entire fibular head is relatively isometric to

the lateral femoral epicondyle throughout a functional range of knee motion, and that there is slightly improved isometry from the posterior aspect of the fibular head to the anterior aspect of the epicondyle, and from the anterior aspect of the fibular head to the posterior aspect of the epicondyle. It should be noted that the isometric region from the posterior aspect of the fibular head to the anterior aspect of the epicondyle represents the anatomic position of the PFL or the static portion of the popliteal tendon. The PFL is thus relatively isometric and can remain functional through a full range of knee motion. The area from the posterolateral corner of the tibia to the lateral femoral epicondyle is not isometric. This region of attachment for a "popliteus bypass procedure" if tensioned near full extension will be supportive in that range but will become somewhat less supportive as the knee passes into greater angles of flexion. In the normal situation, this portion of the PT is tensioned by an intact popliteus muscle belly. Because of the near isometric behavior of the PFL, it is important when reconstructing for PLI to include tissue in the position of the PFL. The reconstruction of the PFL can be performed with either a free graft or by the technique of biceps tenodesis. Wascher et al²⁰ studied the effects of biceps tenodesis after a complete injury to the posterolateral corner. Under varus load and external tibial torque, tenodesis (using a fixation point located 1 cm anterior to the femoral insertion of LCL) restored varus laxity and external tibial rotation.

During posterolateral reconstruction, tissue attached at the fibular head or the posterior lateral corner of the tibia and routed to the lateral femoral epicondyle will resist external tibial rotation and varus rotation. Tissue from the lateral femoral epicondyle to the posterior fibular head has a mechanical advantage over tissue from the epicondyle to the posterolateral corner of the tibia. If the axis of rotation of the tibia relative to the femur is considered to be near the PCL tibial attachment site, then the lever arm of graft attachment to the posterior fibular head is greater by approximately 50% than that of a graft attached to the posterolateral tibia. A graft attached to the posterior fibular head is proportionately more effective in resisting posterolateral rotations. It is therefore appropriate that a posterolateral reconstruction should in most instances include tissue from the posterior aspect of the fibular head to the lateral femoral epicondyle in the position of the PFL. In cases of acute tibio-fibular joint disruption, it is necessary to also include tissue from the lateral femoral epicondyle to the posterolateral corner of the tibia and reconstructing the proximal tibio-fibular joint.^{11,17}

PRIMARY REPAIR SURGICAL TECHNIQUE

Even when reconstructing chronic lateral and posterolateral instabilities, it is important to perform primary repair when possible. Primary repair of acute posterolateral knee injuries is most easily accomplished within the first 2 to 3 weeks postinjury when possible;

however, it is possible to repair these injured tissues in very chronic cases.^{10,13,14} Injuries to the lateral side structures can occur as avulsion of soft tissue from bone at the femoral, tibial, or fibular head attachments; mid-substance interstitial disruption leaving the injured structures in continuity but elongated; and displaced fibular head fractures.³⁻⁵ Our preferred surgical technique for soft tissue avulsion from bone is direct anatomic repair of the injured structures, using suture anchors and permanent braided suture, or screw and ligament washer fixation.

Displaced fibular head fractures cause PLI because most of the lateral side-supporting structures attach to the fibular head, and these structures are no longer able to resist varus stress. Also, when the fibular head displaces in a proximal direction, the lateral, posterolateral capsule, and menisco-tibial ligaments are avulsed from the tibia eliminating these structures' ability to resist varus stress. Our preferred surgical technique for treating displaced fibular head fractures is direct anatomic repair of the injured lateral, posterolateral capsule, and menisco-tibial ligaments, using suture anchors and permanent braided suture, and anatomic open reduction and internal fixation with screw and washer of the displaced fibular head fracture (Figs. 2A, B).

SPLIT BICEPS FEMORIS TENDON TRANSFER SURGICAL TECHNIQUE

There are 2 types of biceps tendon transfer procedures described: the full biceps tendon transfer described by Clancy;¹ and the split biceps tendon transfer (Fig. 3). Although the Clancy procedure is very effective, we prefer the split biceps tendon procedure because it saves the dynamic stabilizing effect of the biceps femoris muscle tendon complex.^{6-8,10,13,14}

The surgical technique for posterolateral reconstruction, using the split biceps tendon transfer to the lateral femoral epicondyle has been described.^{8,10,13,14,16} The requirements for this procedure include an intact proximal tibiofibular joint, the posterolateral capsular attachments to the common biceps tendon should be intact, and the biceps femoris tendon insertion into the fibular head must be intact. This technique recreates the function of the PFL and LCL, tightens the posterolateral capsule, and provides a post of strong autogenous tissue to reinforce the posterolateral corner.

A lateral hockey stick incision is made. The peroneal nerve is dissected free and protected throughout the procedure. The long head and common biceps femoris tendon is isolated, and the anterior two-third is separated from the short head muscle. The tendon is detached proximally and left attached distally to its anatomic insertion site on the fibular head. The strip of biceps tendon should be 12 to 14 cm long. The iliotibial band is incised in line with its fibers, and the fibular collateral ligament and PT are exposed. A drill hole is made 1 cm anterior to the fibular collateral ligament femoral insertion. A longitudinal incision is made in the lateral capsule

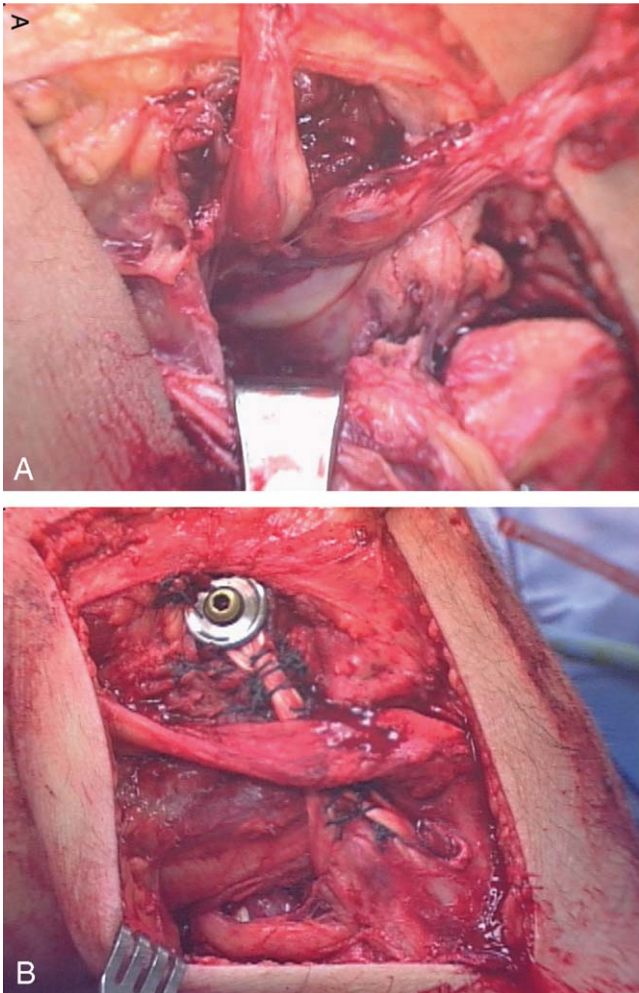


FIGURE 2. A and B, Primary repair of acute PLI type C. These photographs show an acute posterolateral injury type C. The fibular collateral ligament, PT, lateral and posterolateral capsule, PFL, and menisco-tibial ligaments are all avulsed from their insertion sites. Primary anatomic repair is performed using the suture anchor technique. Acute lateral-posterolateral reconstruction is performed using semitendinosus allograft. This patient also had ACL and PCL tears (with permission, Fanelli GC. *Surgical reconstruction for acute PLI of the knee.* *J Knee Surg.* 2005;28:157–162).

just posterior to the fibular collateral ligament. The split biceps tendon is passed medial to the iliotibial band, and secured to the lateral femoral epicondylar region with a screw and spiked ligament washer at the above-mentioned point. The residual tail of the transferred split biceps tendon is passed medial to the iliotibial band, and secured to the fibular head. The posterolateral capsule that had been previously incised is then shifted and sewn into the strut of transferred biceps tendon to eliminate posterolateral capsular redundancy performing the posterolateral capsular shift procedure (Fig. 4A). Cases where the proximal tibiofibular joint has been disrupted, a 2-tailed allograft reconstruction is utilized to control the

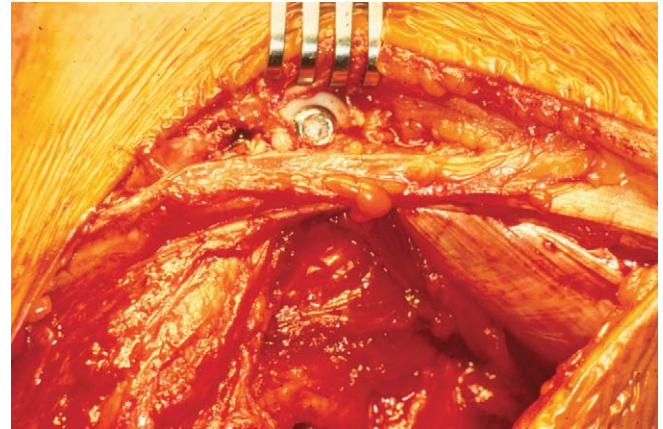


FIGURE 3. Clancy-type full biceps femoris tendon transfer for surgical correction of PLI (with permission, Gregory C. Fanelli, MD).

tibia and fibula independently, in addition to reconstructing the proximal tibio-fibular joint.^{9–14}

FREE TENDON GRAFT SURGICAL TECHNIQUE

When the biceps muscle tendon complex is compromised owing to the patient's injury, it may not be possible to use the split biceps femoris tendon transfer method of reconstruction. These cases will require a free tendon graft surgical procedure combined with the appropriate capsular procedure.

Posterolateral reconstruction with the free graft figure-of-eight technique utilizes semitendinosus autograft or allograft, Achilles tendon allograft, or other soft tissue allograft material. A curvilinear incision is made in the lateral aspect of the knee extending from the lateral femoral epicondyle to the interval between Gerdy tubercle and the fibular head. The fibular head is exposed and a tunnel is created in an anterior to posterior direction at the area of maximal fibular diameter. The tunnel is created by passing a guide pin followed by a cannulated drill 7 mm in diameter. The peroneal nerve is protected during tunnel creation, and throughout the procedure. The free tendon graft is then passed through the fibular head drill hole. An incision is then made in the iliotibial band in line with the fibers directly overlying the lateral femoral epicondyle. The graft material is passed medial to the iliotibial band, and the limbs of the graft are crossed to form a figure of eight. A drill hole is made 1 cm anterior to the fibular collateral ligament femoral insertion. A longitudinal incision is made in the lateral capsule just posterior to the fibular collateral ligament. The graft material is passed medial to the iliotibial band, and secured to the lateral femoral epicondylar region with a screw and spiked ligament washer at the above-mentioned point. The posterolateral capsule that had been previously incised is then shifted and sewn into the strut of figure-of-eight graft tissue material to eliminate posterolateral capsular redundancy. The anterior and posterior limbs of the figure-of-eight graft material are

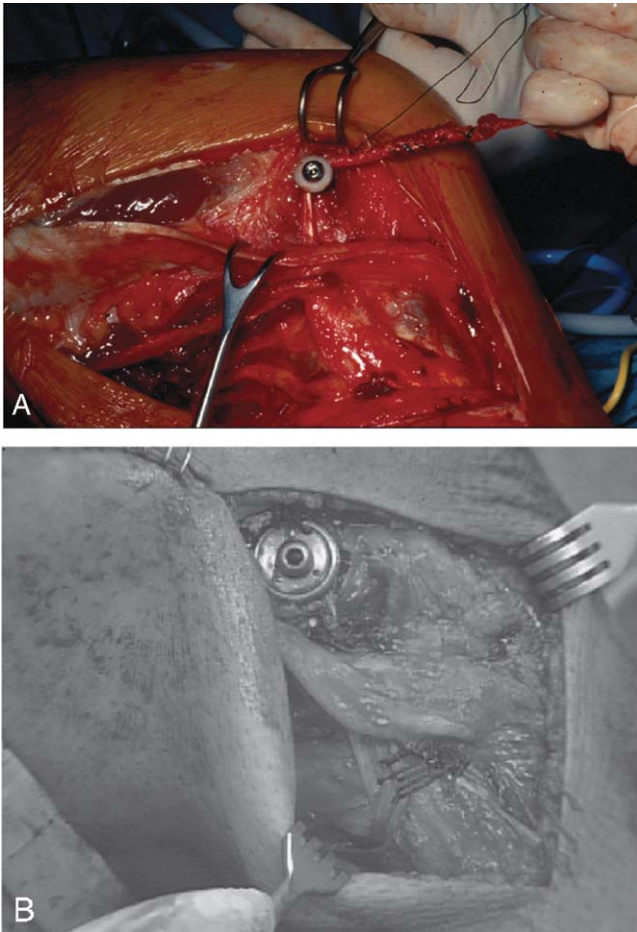


FIGURE 4. A and B, Surgical technique for posterolateral and lateral reconstruction are the split biceps tendon transfer (A), and the allograft or autograft figure-of-eight reconstruction (B) combined with posterolateral capsular shift, and primary repair of injured structures as indicated. These complex surgical procedures reproduce the function of the PFL and the LCL, and eliminate posterolateral capsular redundancy. The split biceps tendon transfer utilizes anatomic insertion sites, and preserves the dynamic function of the long head and common biceps femoris tendon (with permission, Fanelli GC. Surgical reconstruction for acute PLI of the knee. *J Knee Surg.* 2005;28:157–162).

sewn to each other to reinforce and tighten the construct (Fig. 4B). The iliotibial band incision is closed. The procedures described are intended to eliminate posterolateral and varus rotational instability.^{9,11,12,14}

RESULTS

Our surgical experience in posterolateral reconstruction has been in the context of combined PCL-posterolateral corner injuries, and combined ACL-PCL-posterolateral corner injuries. Most recently we have published our 2-to-10 year results on combined PCL-posterolateral reconstructions.¹³ This study presents the 2-to-10 year (24 to 120 months) results of 41 arthroscopically assisted

combined PCL/posterolateral reconstructions evaluated preoperatively and postoperatively using Lysholm, Tegner, and Hospital for Special Surgery knee ligament rating scales, KT 1000 arthrometer testing, stress radiography, and physical examination. The type of study is a case series. This study population included 31 males, 10 females, 24 left, and 17 right chronic PCL/posterolateral knee injuries. All knees had grade 3 preoperative laxity, and were assessed preoperatively and postoperatively with arthrometer testing, 3 different knee ligament rating scales, stress radiography, and physical examination. Arthroscopically assisted PCL reconstructions were performed using the arthroscopically assisted single-femoral tunnel–single-tibial bundle transtibial tunnel PCL reconstruction technique, using fresh-frozen Achilles tendon allografts in all 41 cases. In all 41 cases, PLI was treated with combined biceps femoris tendon transfer, and posterolateral capsular shift procedures.

Postoperative physical exam revealed normal posterior drawer/tibial step-off in 29/41 (70%) of knees. Posterolateral stability was restored to normal in 11/41 (27%) of knees, and tighter than the normal knee in 29/41 (71%) of knees evaluated with the external rotation thigh foot angle test indicating a 98% axial rotation correction rate of the PLI. 30-degree varus stress testing was normal in 40/41 (97%) of knees, and grade 1 laxity in 1/41 (3%) of knees, indicating a 97% correction rate of varus laxity. Postoperative KT 1000 arthrometer testing mean side-to-side difference measurements were 1.80 mm (PCL screen), 2.11 mm (corrected posterior), and 0.63 mm (corrected anterior) measurements. This is a statistically significant improvement from preoperative status for the PCL screen and the corrected posterior measurements ($P \leq 0.001$). The postoperative stress radiographic mean side-to-side difference measurement measured at 90° of knee flexion, and 32 lb of posterior directed proximal tibial force by using the Telos device was 2.26 mm, a statistically significant improvement from preoperative measurements ($P \leq 0.001$). Postoperative Lysholm, Tegner, and Hospital for Special Surgery knee ligament rating scale mean values were 91.7, 4.92, and 88.7, respectively, demonstrating a statistically significant improvement from preoperative status ($P \leq 0.001$).

The conclusions of this study were that combined PCL/posterolateral instabilities can be successfully treated with arthroscopic PCL reconstruction, using fresh-frozen Achilles tendon allograft combined with posterolateral corner reconstruction using biceps tendon transfer combined with posterolateral capsular shift procedure and primary repair. Statistically significant improvement is noted from the preoperative condition at 2-to-10 year follow-up using objective parameters of knee ligament rating scales, arthrometer testing, stress radiography, and physical examination.

We have also recently published our 2-to-10 year results on combined ACL-PCL-posterolateral reconstructions.¹⁰ This study presents the 2-to-10 year (24 to 120 month) results of 35 arthroscopically assisted combined ACL/PCL reconstructions evaluated preoperatively and

postoperatively using Lysholm, Tegner, and Hospital for Special Surgery knee ligament rating scales, KT 1000 arthrometer testing, stress radiography, and physical examination.

The type of study is a case series. This study population included 26 males, 9 females, 19 acute, and 16 chronic knee injuries. Ligament injuries included 19 ACL/PCL/posterolateral instabilities, 9 ACL/PCL/MCL instabilities, 6 ACL/PCL/posterolateral/MCL instabilities, and 1 ACL/PCL instability. All knees had grade 3 preoperative ACL/PCL laxity, and were assessed preoperatively and postoperatively with arthrometer testing, 3 different knee ligament rating scales, stress radiography, and physical examination.

Arthroscopically assisted combined ACL/PCL reconstructions were performed using the single incision endoscopic ACL technique, and the single-femoral tunnel–single-bundle transtibial tunnel PCL technique. PCLs were reconstructed with allograft Achilles tendon (26 knees), autograft BTB (7 knees), and autograft semitendinosus/gracilis (2 knees). ACLs were reconstructed with autograft BTB (16 knees), allograft BTB (12 knees), Achilles tendon allograft (6 knees), and autograft semitendinosus/gracilis (1 knee). MCL injuries were treated with bracing or open primary repair and reconstruction. PLI was treated with biceps femoris tendon transfer, with primary repair as indicated, and posterolateral capsular shift procedures.

Postoperative physical exam revealed normal posterior drawer/tibial step-off in 16/35 (46%) knees, and 19/35 (54%) knees had a tibial step-off decreased 5 mm corresponding to a grade 1 posterior drawer. Normal Lackman and pivot shift tests were obtained in 33/35 (94%) knees. Posterolateral stability was restored to normal in 6/25 (24%) knees, and tighter than the normal knee in 19/25 (76%) knees evaluated with the external rotation thigh foot angle test. This indicated a 100% correction rate of pathologic external rotation. Thirty-degree varus stress testing was normal in 22/25 (88%) knees, and grade 1 laxity in 3/25 (12%) knees. This indicated an 88% correction rate of pathologic varus laxity in these multiple ligament-injured knees.

Thirty degree valgus stress testing was normal in 7/7 (100%) of surgically treated MCL tears, and normal in 7/8 (87.5%) of brace-treated knees.

Postoperative KT-1000 arthrometer testing mean side-to-side difference measurements were 2.7 mm (PCL screen), 2.6 mm (corrected posterior), and 1.0 mm (corrected anterior) measurements, a statistically significant improvement from preoperative status ($P = 0.001$). Postoperative stress radiographic side-to-side difference measurements measured at 90° of knee flexion, and 32 lb of posteriorly directed proximal force were 0 to 3 mm in 11/21(52.3%), 4 to 5 mm in 5/21(23.8%), and 6 to 10 mm in 4/21(19%) of knees. Postoperative Lysholm, Tegner, and HSS knee ligament rating scale mean values were 91.2, 5.3, and 86.8, respectively, demonstrating a statistically significant improvement from preoperative status ($P = 0.001$).

The conclusions of this study were that combined ACL/PCL instabilities can be successfully treated with arthroscopic reconstruction of the cruciate ligaments and the appropriate collateral ligament surgery. Statistically significant improvement is noted from the preoperative condition at 2-to-10 year follow-up using objective parameters of knee ligament rating scales, arthrometer testing, stress radiography, and physical examination. Posterolateral stability was restored to normal in 6/25 (24%) knees, and tighter than the normal knee in 19/25 (76%) knees evaluated with the external rotation thigh foot angle test. This indicated a 100% correction rate of pathologic external rotation. Thirty-degree varus stress testing was restored to normal in 22/25 (88%) knees, and grade 1 laxity in 3/25 (12%) knees. This indicates an 88% correction rate of pathologic varus laxity in these multiple ligament-injured knees utilizing primary posterolateral repair combined with biceps femoris tendon transfer and posterolateral capsular shift reconstruction.

Our most recent series presents the 2-year follow-up results of 15 arthroscopically assisted ACL PCL reconstructions using the Arthrotek graft-tensioning boot.¹⁵ This study group consists of 11 chronic and 4 acute injuries. These injury patterns included 6 ACL PCL PLC injuries, 4 ACL PCL MCL injuries, and 5 ACL PCL PLC MCL injuries. The Arthrotek tensioning boot was used during the procedures as in the surgical technique described above. All knees had grade 3 preoperative ACL/PCL laxity, and were assessed preoperatively and postoperatively using Lysholm, Tegner, and Hospital for Special Surgery knee ligament rating scales, KT 1000 arthrometer testing, stress radiography, and physical examination.

Arthroscopically assisted combined ACL/PCL reconstructions were performed using the single incision endoscopic ACL technique, and the single-femoral tunnel–single-bundle transtibial tunnel PCL technique. PCLs were reconstructed with allograft Achilles tendon in all 15 knees. ACLs were reconstructed with Achilles tendon allograft in all 15 knees. MCL injuries were treated surgically using primary repair, posteromedial capsular shift, and allograft augmentation as indicated. PLI was treated with allograft semitendinosus free graft, with or without primary repair, and posterolateral capsular shift procedures as indicated. The Arthrotek graft tensioning boot was used in this series of patients.

Postreconstruction physical examination results revealed normal posterior drawer/tibial step-off in 13/15 (86.6%) of knees. Normal Lackman test in 13/15 (86.6%) knees, and normal pivot shift tests in 14/15 (93.3%) knees. Posterolateral stability was restored to normal in all knees with PLI when evaluated with the external rotation thigh foot angle test (9 knees equal to the normal knee and 2 knees tighter than the normal knee). Thirty-degree varus stress testing was restored to normal in all 11 knees with posterolateral lateral instability. Thirty and zero-degree valgus stress testing was restored to normal in all 9 knees with medial side laxity. Postoperative KT-1000 arthrometer testing mean

side-to-side difference measurements were 1.6 mm (range – 3 to 7 mm) for the PCL screen, 1.6 mm (range –4.5 to 9 mm) for the corrected posterior, and 0.5 mm (range – 2.5 to 6 mm) for the corrected anterior measurements, a significant improvement from preoperative status. Postoperative stress radiographic side-to-side difference measurements measured at 90° of knee flexion, and 32 lb of posteriorly directed proximal force, using the Telos stress radiography device were 0 to 3 mm in 10/15 knees (66.7%), 4 mm in 4/15 knees (26.7%), and 7 mm in 1/15 knees (6.67%). Postoperative Lysholm, Tegner, and HSS knee ligament rating scale mean values were 86.7 (range 69 to 95), 4.5 (range 2 to 7), and 85.3 (range 65 to 93), respectively, demonstrating a significant improvement from preoperative status.

The study group demonstrates the efficacy and success of using a mechanical graft-tensioning device (Arthrotek graft tensioning boot) in single-bundle single-femoral tunnel arthroscopic PCL reconstruction, and the importance of successful posterolateral reconstruction in the overall success of the surgical procedure.

SUMMARY

PLI is common with PCL tears and is less common with ACL tears, and isolated PLI is rare. There are varying degrees of PLI with respect to pathologic external tibial rotation, and varus instability. Surgical treatment of PLI must address all components of the PLI (PFL, LCL, and the lateral-posterolateral capsule), and other structural injuries. Successful PCL (and ACL) surgery depends on recognition and treatment of posterolateral corner injuries.

REFERENCES

1. Clancy WG Jr. Repair and reconstruction of the posterior cruciate ligament. In: Chapman MW, ed. *Operative Orthopaedics*. Philadelphia, PA: JB Lippincott; 1998:1651–1665.
2. Fanelli GC. Surgical reconstruction for acute posterolateral injury of the knee. *J Knee Surg*. 2005;28:157–162.
3. Fanelli GC. PCL injuries in trauma patients. *Arthroscopy*. 1993;9:291–294.
4. Fanelli GC, Edson CJ. PCL injuries in trauma patients: Part II. *Arthroscopy*. 1995;11:526–529.
5. Fanelli GC, Giannotti BF, Edson CJ. Current concepts review. The posterior cruciate ligament arthroscopic evaluation and treatment. *Arthroscopy*. 1994;10:673–688.
6. Fanelli GC, Giannotti BF, Edson CJ. Arthroscopically assisted combined anterior and posterior cruciate ligament reconstruction. *Arthroscopy*. 1996;12:5–14.
7. Fanelli GC, Giannotti BF, Edson CJ. Arthroscopically assisted combined posterior cruciate ligament/posterior lateral complex reconstruction. *Arthroscopy*. 1996;12:521–530.
8. Fanelli GC, Feldmann DD. Management of combined ACL/PCL/posterolateral complex injuries of the knee. *Oper Tech Sports Med*. 1999;7:143–149.
9. Fanelli GC, ed. *Posterior Cruciate Ligament Injuries: A Practical Guide to Management*. New York: Springer-Verlag; 2001.
10. Fanelli GC, Edson CJ. Arthroscopically assisted combined ACL/PCL reconstruction. 2–10 year follow-up. *Arthroscopy*. 2002;18:703–714.
11. Fanelli GC, Larson RV. Practical management of posterolateral instability of the knee. *Arthroscopy*. 2002;18:1–8.
12. Fanelli GC. *The Multiple Ligament Injured Knee. A Practical Guide to Management*. New York: Springer-Verlag; 2004.
13. Fanelli GC, Edson CJ. Combined posterior cruciate ligament—posterolateral reconstruction with Achilles tendon allograft and biceps femoris tendon tenodesis: 2–10 year follow-up. *Arthroscopy*. 2004;20:339–345.
14. Fanelli GC, Orcutt DR, Edson CJ. Current concepts: the multiple ligament injured knee. *Arthroscopy*. 2005;21:471–486.
15. Fanelli GC, Edson CJ, Orcutt DR, et al. Treatment of combined ACL PCL medial lateral side injuries of the knee. *J Knee Surg*. 2005;28. In press.
16. Muller W. *The Knee: Form, Function, and Ligamentous Reconstruction*. New York: Springer-Verlag; 1983.
17. Sidles JA, Larson RV, Garbini JL, et al. Ligament length relationships in the moving knee. *J Orthop Res*. 1988;6:593–610.
18. Skyhar MJ, Warren RF, Oritz GJ, et al. The effects of sectioning the posterior cruciate ligament and the posterolateral complex on the articular contact pressure within the knee. *J Bone Joint Surg Am*. 1993;75:694–699.
19. Veltri DM, Warren RF. Posterolateral instability of the knee. *J Bone Joint Surg*. 1994;76-A:460–472.
20. Wascher DC, Grauer JD, Markolf KL. Biceps tendon tenodesis for posterolateral instability of the knee. An in vitro study. *Am J Sports Med*. 1993;21:400–406.